

Toxic epidermal necrolysis induced by radiotherapy

Agnieszka B. Owczarczyk-Saczonek, Waldemar J. Placek, Joanna Rybak-d'Obyrn, Ewa Wygonowska

Chair and Department of Dermatology, Sexually Transmitted Diseases and Clinical Immunology, Municipal Hospital Centre, Olsztyn, Poland
Head: prof. Wademar Placek MD, PhD

Przeegl Dermatol 2013, 100, 363–366

KEY WORDS:
radiotherapy, cancer
of bladder, toxic epidermal
necrolysis.

**ADDRESS
FOR CORRESPONDENCE:**
Agnieszka B. Owczarczyk-
Saczonek
Chair and Department
of Dermatology,
Sexually Transmitted Diseases
and Clinical Immunology
Municipal Hospital Centre
al. Wojska Polskiego 30
10-595 Olsztyn, Poland
Phone: +48 601057800,
+48 89 678 66 70
Fax: +48 89 678 66 75
E-mail: aganek@wp.pl

ABSTRACT

Introduction. Toxic epidermal necrolysis (TEN) or Lyell syndrome is a life-threatening adverse drug reaction, characterized by widespread erythema, necrosis, and bullous detachment of the epidermis and mucous membranes. The estimated mortality associated with this illness varies widely in different reports, from 30–40%. In 90% of cases is associated with the exposure to the drug. Radiotherapy rarely triggers the illness.

Objective. Presentation of the TEN provoked by radiotherapy.

Case report. We present a case of 82-year-old patient with TEN provoked by radiotherapy which was used to treat a cancer of bladder. On admission the lesions covered about 60% of the total body surface area, involving oral mucosa and conjunctiva. Fever and oliguria were observed. Diagnostic investigation revealed leukocytosis, increased level of creatinine, glycosuria and proteinuria. After treatment with cyclosporine, 4 mg/kg, and methylprednisolon 48 mg, the skin, oral mucosa and conjunctiva lesions were cured within 3 weeks and there was the normalization of laboratory abnormalities.

Conclusions. In some cases reported in literature, patients with primary and metastatic brain tumors develop TEN after treatment with phenytoin and its derivatives combined with radiation therapy. Such a reaction is called EMPACT (erythema multiforme associated with phenytoin and cranial radiation therapy). The development of TEN after radiation therapy is seldom reported.

INTRODUCTION

Toxic epidermal necrolysis (TEN), also known as Lyell's syndrome, is a severe drug-induced reaction associated with a mortality rate of 30–40%. The condition is manifested as acute necrolysis of the epidermis and mucosal epithelium in the form of flaccid exfoliating blisters covering over 30% of the body surface [1, 2]. The syndrome has a sudden onset and severe course with fever and electrolyte and metabolic disturbances resulting from epidermal detachment. Toxic epidermal necrolysis occurs mainly in the adult population and it is associated with drug exposure in 90% of cases [3, 4]. The most common triggers of the condition are anti-

convulsants (carbamazepine, phenytoin, phenobarbital, valproic acid, lamotrigine), sulphonamides, antibiotics, allopurinol, NSAIDs (oxicams) and antiviral drugs (abacavir, nevirapine) [2, 5, 6].

Radiotherapy (RT) is one of the most important methods of cancer treatment which is associated with well-known adverse skin reactions. Approximately 5% of patients may suffer an acute radiation reaction manifesting as erythema and exfoliation – or late reactions in the form of fibrosis and telangiectasias [7]. Radiotherapy, however, is rarely a factor triggering TEN [3].

The pathophysiology of Lyell's syndrome has not been fully elucidated. It is known to be linked to the

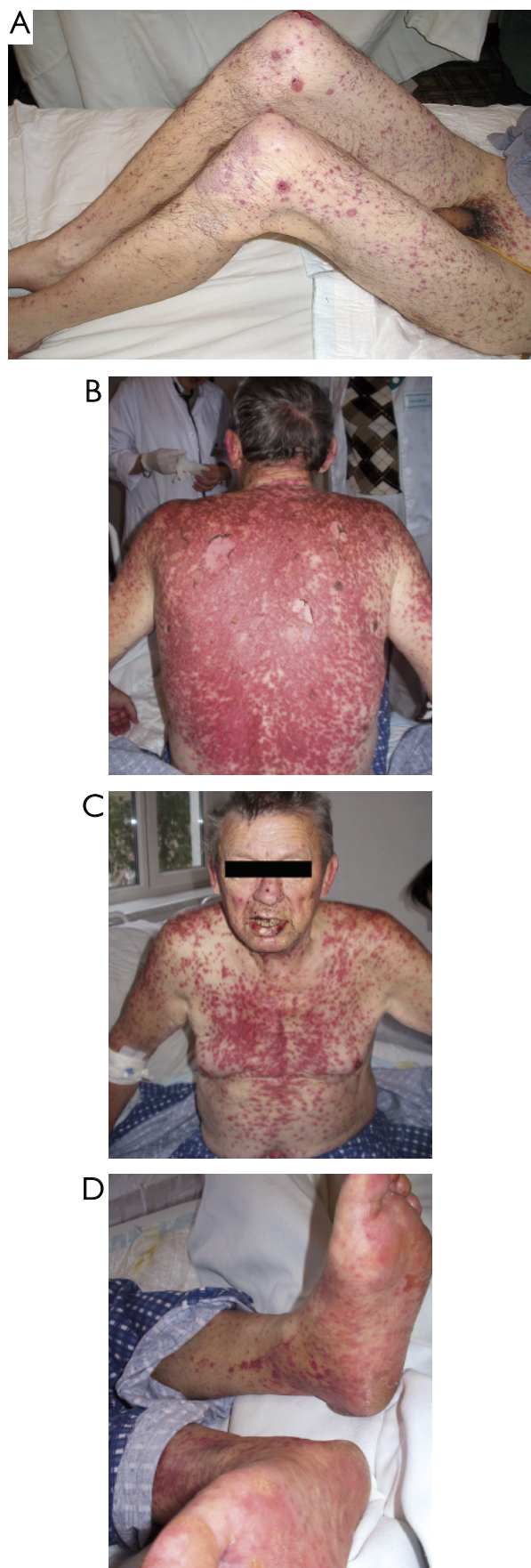


Figure 1 A–D. Patient at the day of admission to the Dermatology Department

cytotoxic immune response leading to the destruction of keratinocytes expressing foreign antigens [5]. This is referred to as delayed-type hypersensitivity response IV c which involves CD8+ T cells, causing apoptosis [8]. The drug appears to induce HLA class I expression on the surfaces of keratinocytes. The antigen binds to the cell surface, following which directly stimulated T cells become cytotoxic lymphocytes (Tc/CD8+) that induce apoptosis by Fas-ligand reaction. The resulting FasL complex is expressed on the surface of cytotoxic lymphocytes and binds to the receptor on target cells. Other mediators of apoptosis are cytotoxic proteases produced by cytotoxic lymphocytes, NK and NKT cells, including perforins and granzyme B, which form channels in the membranes of target cells, ultimately destroying them. Apoptosis induces spongiosis of keratinocytes, resulting in the formation of vesicles and then blisters, followed by epidermal exfoliation [2, 4, 5, 8, 9].

CASE REPORT

The patient, an 82-year-old man, was admitted to the Dermatology Department on 22 April 2005 due to erythematous oedematous lesions with coexisting exfoliation of the epidermis over an area irradiated with X-ray 3 days prior to the hospitalization (Figure 1 A–D). The patient had received radical radiation therapy (X 6/25 MV at a dose of 4,500 Gy and X 15 MV at a dose of 2,000 Gy) for the preceding two months due to inoperable cancer of the bladder which was diagnosed in January 2005. On admission, the skin lesions covered ca. 60% of the patient's body surface. They presented as confluent erythematous oedematous patches, flaccid blisters with exfoliating epidermis affecting the skin of the trunk and extremities. The lesions were especially pronounced on the patient's hands and feet. Mucous membranes of the mouth revealed isolated erythematous areas. Crusting scabs were observed in the lip region, and the patient's conjunctiva and eyelids were covered with erythema. In addition, the patient had signs of oliguria and fever (38°C). Laboratory tests revealed abnormalities including leukocytosis (30.9 G/l) and creatinine concentration of 2.5 mg/dl. General urine analysis showed an elevated sugar level (100 mg/dl) and the presence of protein (30 mg/dl). Skin swab tests and blood and urine cultures were sterile. Pharmacological treatment with cyclosporin A (4 mg/kg body weight), methylprednisolone (48 mg) and cefuroxime (2 × 0.5 mg) was introduced. Within three weeks of treatment, the skin lesions were almost completely healed, and results of laboratory tests normalized (WBC 4.11 G/l, creatinine 1.24 mg/dl).

The patient was readmitted 2 months after discharge due to symptoms of acute generalized exanthematous pustulosis (AGEP) (hospitalization from 30 June 2005

until 12 July 2005). On admission, the patient had erythematous areas in the inguinal and medial femoral regions, distinctive for the presence of multiple small milky-white pustules around the periphery of the lesions, with coexisting epidermal exfoliation. Laboratory test abnormalities included leukocytosis (10.4 G/l) with neutrophilia (85%), anaemization (RBC 3.61 T/l, HGB 10.8 g/dl), ESR 64 mm/h, creatinine concentration 1.4 mg/dl. Chest radiography demonstrated parenchymal lesions in the right inferior lung field (consistent with a metastatic focus of bladder cancer). The patient received methotrexate 15 mg/week and prednisone 30 mg/day. Within 13 days, the skin lesions were healed and the patient was discharged with referral to the Pulmonary Diseases Unit for further diagnosis of pulmonary abnormalities.

DISCUSSION

Ionizing radiation causes a variety of adverse skin reactions, the most common of which is acute radiation dermatitis. Radiation-induced Stevens-Johnson syndrome (SJS) and TEN, however, occur extremely rarely [3, 10]. There are case reports of patients with primary or metastatic brain tumours who are treated with derivatives of phenytoin combined with radiation therapy [3, 10, 11]. In 1988 Delattre *et al.* described eight such cases, arguing that the two treatment modalities (pharmacotherapy and radiation therapy) applied in combination may be conducive to the development of TEN [11]. A new term, EMPACT (erythema multiforme associated with phenytoin and cranial radiation therapy), was thus proposed [10, 11]. An analysis of 24 cases of this drug reaction failed to show any correlations between the dose of phenytoin, irradiation and histopathological tumour type. The skin lesions subsided after the discontinuation of the triggering drug. No mortalities were recorded, either [12]. Later, however, cases of disease induced by radiotherapy in combination with different antiepileptic drugs (carbamazepine, phenobarbital) were reported [10]. Although the pathogenesis of these reactions is unknown, several hypotheses have been advanced. Firstly, radiotherapy may lead to the deficiency of epoxide hydrolase, an enzyme responsible for the elimination of toxic metabolites of phenytoin. Secondly, radiotherapy may affect the functions of suppressor T cells [10]. Furthermore, ionizing radiation may change the natural metabolism of phenytoin, resulting in the production of substances that are directly toxic to cells or, as happens, are capable of stimulating secondary immune response [12]. Vern-Gross and Kowal-Vern [13] conducted a cross-sectional metaanalysis of patients treated with radiotherapy who developed erythema type reactions. The authors assessed 89 medical reports of 165 patients, published in the period 1903–2011. In

57 out of 151 assessed cases (38%) the reactions were reported to be erythema multiforme, 46 (30.5%) – SJS, 14 (9%) – SJS/TEN overlap syndrome, and 34 (22.5%) – TEN. The most common drugs taken during radiation therapy were antiepileptics and amifostine (a drug used to reduce the side effects of radiation therapy, scavenging the resulting free radicals) [13]. Yoshitake *et al.* [14] reported erythematous reactions developing after the radiotherapy of cancers not affecting the head. Stevens-Johnson syndrome signs occurred after radiation therapy in two women suffering from breast cancer and cervical cancer. In the two reported cases, skin lesions regressed after 2–4 weeks [14]. Interestingly, Hafiji *et al.* [7] reported the opposite reaction. Toxic epidermal necrolysis was diagnosed in a 49-year-old black race patient with metastatic *rhabdomyosarcoma*, while X-ray radiation therapy is likely to have had a protective effect. The patient developed TEN covering 60% of the body surface during the treatment of pneumonia with amoxicilline combined with clavulanic acid and levofloxacin. The remaining skin area was unchanged only in previously irradiated regions (a distinctly circumscribed area on the chest and an exactly corresponding area on the back). The patient had completed radiation therapy of this area as the superior vena cava region three months before. It is the first reported case in which RT appears to have played a protective role. It is possible that radiotherapy inactivates cytotoxic lymphocytes which are key for TEN aetiology [7]. The effect of the reaction is likely to be dependent on the patient's genetic predisposition. It has been demonstrated in the Chinese population that the development of carbamazepine-induced SJS/TEN is closely correlated with the presence of HLA-B* 1502 [7, 15]. Studies conducted among Europeans, however, have failed to demonstrate any relationship between the reactions and HLA-B* 1502 for carbamazepine, sulfamethoxazole, lamotrigine and oxycams [4, 16]. This may be a mechanism explaining why radiotherapy triggers SJS/TEN in some patients, while in others it has a protective effect.

References

1. Roujeau J.C., Stern R.S.: Severe adverse cutaneous reactions to drugs. *N Engl J Med* 1994, 331, 1272-1285.
2. Schwartz R.A., McDonough P.H., Lee B.W.: Toxic epidermal necrolysis. Part I. Introduction, history, classification, clinical features, systemic manifestations, etiology, and immunopathogenesis. *J Am Acad Dermatol* 2013, 69, 173.e1-13.
3. Elazzazy S., Abu Hassan T., El Seid A., Jacob C.M.: Toxic epidermal necrolysis associated with antiepileptic drugs and cranial radiation therapy. *Case Rep Oncol Med* 2013, 2013, 415031.
4. Harr T., French L.E.: Toxic epidermal necrolysis and Stevens-Johnson syndrome. *Orphanet J Rare Dis* 2010, 5, 39.
5. Pereira F.A., Mudgil A.V., Rosmarin D.M.: Toxic epidermal necrolysis. *J Am Acad Dermatol* 2007, 56, 181-200.
6. Thammakumpee J., Yongsiri S.: Characteristics of toxic epidermal necrolysis and Stevens-Johnson syndrome: a 5-year retrospective study. *J Med Assoc Thai* 2013, 96, 399-406.

7. **Hafiji J., Orpin S., Roberts C., Heagerty A., Lewis H.:** Radiotherapy: a protective role for toxic epidermal necrolysis? *Br J Dermatol* 2010, 162, 1138-1158.
8. **Czarnobilska E., Obtulowicz K., Wsolek K.:** Type IV hypersensitivity reaction and its subtypes. *Przegl Lek* 2007, 64, 506-508.
9. **Abe R., Shimizu T., Shibaki A., Nakamura H., Watanabe H., Shimizu H.:** Toxic epidermal necrolysis and Stevens-Johnson syndrome are induced by soluble Fas ligand. *Am J Pathol* May 2003, 162, 1515-1520.
10. **Fernández F.A., Pintor E., Quesada R., Garcésa F.J.:** Toxic epidermal necrolysis induced by phenytoin and whole brain radiotherapy. *Actas Dermosifiliogr* 2007, 98, 483-485.
11. **Delattre J.Y., Safai B., Posner J.B.:** Erythema multiforme and Stevens-Johnson syndrome in patients receiving cranial irradiation and phenytoin. *Neurology* 1988, 38, 194-198.
12. **Ahmed I., Reichenberg J., Lucas A., Shehan J.M.:** Erythema multiforme associated with phenytoin and cranial radiation therapy: a report of three patients and review of the literature. *Int J Dermatol* 2004, 43, 67-73.
13. **Vern-Gross T.Z., Kowal-Vern A.:** Erythema multiforme, Stevens-Johnson syndrome, and toxic epidermal necrolysis syndrome in patients undergoing radiation therapy: a literature review. *Am J Clin Oncol* 2012, 13 [Epub ahead of print].
14. **Yoshitake T., Nakamura K., Shioyama Y., Sasaki T.:** Erythema multiforme and Stevens-Johnson syndrome following radiotherapy. *Radiat Med* 2007, 25, 27-30.
15. **Man C.B., Kwan P., Baum L., Yu E., Lau K.M., Cheng A.S., Ng M.H.:** Association between HLA-B*1502 allele and antiepileptic drug-induced cutaneous reactions in Han Chinese. *Epilepsia* 2007, 48, 1015-1018.
16. **Nassif A., Bensussan A., Boumsell L., Deniaud A., Moslehi H., Wolkenstein P., et al.:** Toxic epidermal necrolysis: effector cells or drug specific cytotoxic T cells. *J Allergy Clin Immunol* 2004, 114, 1209-1215.

Received: 25 X 2013

Accepted: 26 XI 2013